

## Observational Study

# Safety of Interlaminar Cervical Epidural Injections: Experience With 12,168 Procedures in a Single Pain Clinic

David M. Schultz, MD<sup>1,2</sup>, Jonathan M. Hagedorn, MD<sup>3</sup>, Alaa Abd-Elseyed, MD<sup>4</sup>, and Scott Stayner, MD, PhD<sup>1</sup>

From: <sup>1</sup>Nura Pain Clinic, Minneapolis, MN; <sup>2</sup>Department of Anesthesia, Critical Care and Pain Medicine, University of Minnesota, Twin Cities, MN; <sup>3</sup>Department of Anesthesiology and Perioperative Medicine, Division of Pain Medicine, Mayo Clinic, Rochester, MN; <sup>4</sup>Department of Anesthesiology, University of Wisconsin School of Medicine and Public Health, Madison, WI

Address Correspondence:  
David M. Schultz, MD  
Nura Pain Clinics  
2104 Northdale Blvd NW,  
Ste 220,  
Minneapolis, MN 55433  
E-mail:  
dschultz@nuraclinics.com

Disclaimer: There was no external funding in the preparation of this manuscript.

Conflict of interest: Each author certifies that he or she, or a member of his or her immediate family, has no commercial association (i.e., consultancies, stock ownership, equity interest, patent/licensing arrangements, etc.) that might pose a conflict of interest in connection with the submitted manuscript.

Manuscript received: 05-05-2021  
Revised manuscript received:  
09-08-2021  
Accepted for publication:  
09-27-2021

Free full manuscript:  
[www.painphysicianjournal.com](http://www.painphysicianjournal.com)

**Background:** Cervical epidural steroid injections have long been utilized to treat intraspinal inflammation causing cervicgia and/or cervical radiculopathy, and much has been written about safety and efficacy. There are published opinions, without evidence basis, that these injections should not be performed above C7-T1 for fear of dural puncture, spinal cord injury, and other complications that might occur more frequently at higher spinal levels. However, many experienced interventional pain physicians believe that epidural injections targeted to the level of spinal inflammation may be more effective. Although medication injected at the lowest cervical level C7-T1 may ascend to higher spinal levels, it often does not since inflammation and swelling at the cervical level of pathology may increase epidural pressure causing the injectate to move caudally down the path of least resistance.

**Objectives:** We sought to provide evidence for safety of posterior interlaminar epidural steroid injections at spinal levels at and above C7-T1 and to outline a 'best practices' approach to posterior cervical epidural injection based on experience with over 12,000 injections over 2 decades. We provide a discussion of cervical spinal anatomy, preferred technique for injection, and briefly review published literature to date regarding safety and efficacy of this procedure.

**Study Design:** Retrospective case series.

**Setting:** Single center, private practice institution.

**Methods:** To document safety of interlaminar cervical epidural injections at levels above C7-T1, we conducted a retrospective study where we queried our electronic medical record database for information regarding 12,168 interlaminar cervical epidural steroid injections performed on 6,158 unique patients during a 14-year period by 5 different board-certified interventional pain physicians using similar technique within a single medical practice. Each injection was performed using fluoroscopic guidance with cervical epidurography routinely performed prior to injection of a therapeutic steroid and local anesthetic mixture. We found 129 minor complications (complications that did not require medical care beyond the post-anesthesia care unit [PACU] and 7 complications which we considered serious (required care beyond PACU stay), although no patients suffered paralysis or death. There was no correlation between spinal level of injection and complication rates.

**Results:** Our most common spinal level for injection was C5-6, followed closely by C6-7. Hundreds of injections were performed at spinal levels above C5-6 with the most cephalad level C2-3.

**Limitations:** Retrospective design.

**Conclusion:** Our article supports the contention that interlaminar cervical epidural injections above C7-T1 are safe. Complication rates were not increased with cervical injections cephalad to C7-T1.

**Key words:** Cervical epidural steroid injection, complications, outcomes, chronic pain, cervical radiculopathy, cervical pain, interventional pain, case series

**Pain Physician 2022; 25:49-58**

**T**he first documented lumbar epidural steroid injection occurred in Italy in 1952, and therapeutic lumbar epidural steroid injections became increasingly common in the United States (US) in the 1960s and 70s (1-4). Cervical epidural steroid injections without image guidance were previously described in pain management textbooks in the 1970s and 80s and, with the advent of fluoroscopic image guidance in the 1990s, have been increasingly used to treat cervical pain syndromes over the past 30 years (2-19). Between 2000 and 2018, there were about 36,000,000 epidural steroid injections performed on Medicare patients in the US, with approximately 8.9% of these posterior interlaminar cervical or thoracic epidurals and 2.7% transforaminal cervical or thoracic epidurals (17,18).

There have been various published opinions regarding cervical epidural injection as to appropriate technique, optimal spinal level, and type of steroid preparation, but there are few large case series or randomized controlled studies to guide practitioners (10-16). However, there are published opinions that these injections should not be performed above C7-T1 for fear of dural puncture, spinal cord injury, and other complications that might occur more frequently at higher spinal levels (20-22). The Multisociety Pain Workgroup (MPW) published safety recommendations in 2015 (23,24) which advocated multiple views of imaging and that interlaminar epidural steroid injections be performed at the C7-T1 level, but preferably not higher than C6-C7. Following an extensive campaign by the American Society of Interventional Pain Physicians (ASIPP), the Food and Drug Administration (FDA) has not adapted the MPW safety recommendations; thus, these remained as opinions from societies and experts (25,26) which were approved by MPW, but not by the FDA or the FDA Safe Use Initiative panel (23-27).

Since 2015, multiple studies have been published (28-35). A retrospective evaluation by Manchikanti et al (28) found the incidence of dural puncture, approximately 1%, with no statistical difference between injections performed at C5-C6, C6-C7, or C7-T1. In this retrospective evaluation (28), the authors reviewed complications in 4,396 consecutive cervical interlaminar epidural injections performed over a period of 3 years. They reported that dural puncture was equally prevalent, though very rare, regardless of the level of needle entry into the epidural space, with an overall dural puncture rate of 1.4%, with 1.8% at C5-C6 level, 0.87% at C6-C7 level, and 1.71% at the C7-T1 level.

Manchikanti et al (30) also published a prospective evaluation of complications of 10,000 fluoroscopically directed epidural injections in 2012. In this assessment, the authors included 2,300 cervical interlaminar epidurals with reports of dural puncture of 1% in the cervical region and intravascular entry of 4.1%.

In the field of pain medicine, epidural injections are typically performed to deposit a therapeutic agent, such as a corticosteroid/local anesthetic admixture, into the epidural space to achieve a beneficial effect. This may be accomplished by entering the epidural space at various spinal levels using a variety of techniques. For many situations, the transforaminal approach to epidural access has several advantages over other techniques, but the use of cervical transforaminal injections to treat cervical pain syndromes has declined over recent years because of documented cases of spinal cord infarction from inadvertent injection of particulate steroid into radiculomedullary arteries present in cervical foramina (16,29,36). This risk is obviated with posterior interlaminar epidural injection because arteries delivering blood to the spinal cord parenchyma course through neural foramina and are not present in the posterior epidural space. Although transforaminal epidural injections may provide a more direct route to the therapeutic target, the anterior epidural space and dorsal root ganglion may also be accessed using interlaminar approaches. Interlaminar cervical epidural injections are technically easy to perform, relatively comfortable for the patient, and allow for wide dispersal of medication to treat multilevel and bilateral radicular pain patterns with a single injection (10) [see fluoroscopy images in Appendix 2].

The current medical literature supports the safe and effective use of cervical interlaminar epidural injection using fluoroscopic guidance based on observational studies, randomized controlled trials, systematic reviews, and guidelines (10-15,18). The objective of our report is to describe the safety and complication rates for cervical interlaminar epidural steroid injections of particulate corticosteroid at various cervical spinal levels in over 12,000 procedures performed in a private practice pain clinic.

## **METHODS**

This study is a retrospective chart review from a single medical practice analyzing both structured and unstructured data points contained within our electronic medical record (NextGen) for fluoroscopically guided posterior interlaminar cervical epidural

steroid injections performed between 2006 and 2020. All patients who were referred to our surgery center for a cervical epidural steroid injection were included in the study. All 12,168 separate procedures were performed on 6158 individual patients by one of 5 different board-certified interventional pain physicians in a single pain clinic medical practice in Minneapolis, MN. All patients were evaluated after the procedure in the post-anesthesia care unit (PACU), and any complications were recorded in the electronic medical record (EMR). Patients were also contacted via telephone within 48 hours of the procedure, and any negative side effects from the procedure were recorded in the EMR. The EMR was reviewed for patient demographic, clinical data, and procedural specifics, including age, gender, comorbidities, diagnosis for injection, spinal level of injection, needle type, injectate information (including contrast, local anesthetic, and steroid) and immediate complications. A descriptive statistical analysis was performed on the dataset to analyze the primary outcome of whether a patient had any complications during or immediately after the procedure. We manually reviewed the medical record of any patient identified as having a procedure-related complication to determine the nature of the event. In addition, we cross-checked all procedures for complications with a chart review for prolonged stay in the PACU after the procedure, any patient transported to a hospital or emergency room from PACU after the procedure, and any medical malpractice claims filed after any of the procedures. All data were de-identified prior to publication. We defined minor complications as those which occurred during or immediately after the procedure and resulted in an unexpected patient condition that resolved during the usual PACU observation period and did not require further medical care. We defined a serious complication as any event that was considered potentially life-threatening without treatment, required resuscitation efforts, medical transport from our facility, emergency room transfer or hospital admission, and resulted in a prolonged recovery room stay (over 2 hours) or caused patient disability lasting beyond pain clinic discharge.

### **Technique Information**

Our patients are positioned prone with a cervical pillow on a carbon-fiber, diving board-type pain management table. We use a C-arm fluoroscope to visualize cervical anatomy as we advance a Tuohy epi-

dural needle into the dorsal epidural space with loss-of-resistance (LOR) technique using an air-filled, plastic LOR syringe. We then connect the needle to a 3-inch extension catheter and inject water-soluble contrast to obtain an epidurogram. Finally, we inject a 5mL therapeutic admixture of particulate steroid and local anesthetic using a 10 mL syringe (See Appendix 1).

### **Anesthesia Information**

Local anesthetic was used to anesthetize the skin and supraspinal tissues for all patients. Approximately 60% of patients also had IV conscious sedation, typically with midazolam and fentanyl at standard dosages of 2 mg and 100 mcg, respectively. Additional low dose IV ketamine was used rarely for very anxious, opioid-tolerant patients. All patients remained conscious during the procedure, and no patient underwent monitored anesthesia care (MAC) or general anesthesia.

### **Injectate Information**

#### **Contrast**

In nearly all patients, Omnipaque contrast (240 mg/mL) was utilized to confirm epidural needle location (99.9%). Due to iodine contrast allergy, a gadolinium-based agent was used in 2 patients. Similarly, 80% of patients received 3 mL of water-soluble x-ray contrast injected into the epidural space.

#### **Local Anesthetic**

Lidocaine 1% was routinely used for skin anesthesia. Our standard steroid admixture contained 2 mL bupivacaine 0.25% mixed with particulate steroid.

#### **Steroid**

Our standard steroid dose was methylprednisolone 80 mg (range 40 mg-120 mg) with an undiluted concentration 40 mg/mL or 80 mg/mL.

## **RESULTS**

---

### **Demographics**

Regarding the overall sample, the mean patient age was 59 + 14 years (range 16 years to 106 years) (Fig. 1). There were 4092 (66.5%) women and 2066 (33.5%) men. The most common indications for injection included cervical disc displacement, cervical degenerative disc disease, cervical spondylosis, and post-spinal surgery syndrome. Comorbidities were common among patients in the study. We determined that 4401 (71.5%)

patients had at least one comorbidity, 2176 (35.3%) had at least 2 comorbidities, and 117 (1.9%) had 3 or more comorbidities (Fig. 2). The most common comorbidities were depression, hypertension, and diabetes.

Approximately half of the patients (52.7%; n = 3247) had only one procedure over the period studied. However, 1673 (27.2%) patients had 2 procedures, 623

(10.1%) had 3 procedures, and 615 (10.0%) had more than 3 procedures (Fig. 3). Injections were evenly performed throughout the reviewed years.

**Cervical Level**

Injections were performed at every interlaminar level from C2-3 to C7-T1, with the majority of proce-

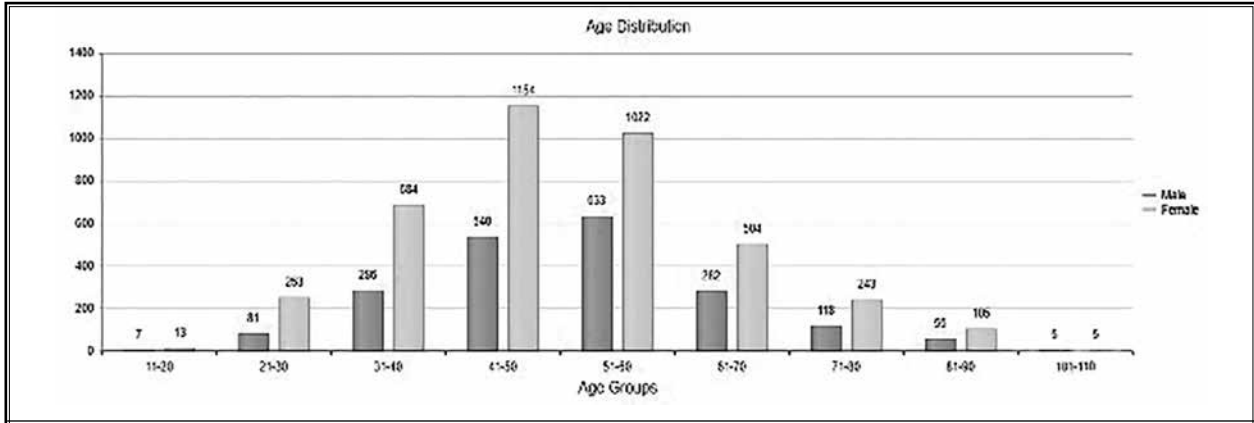


Fig. 1. Age distribution of patients for whom a cervical epidural steroid injection was performed.

Groups	Total	Diabetes	Hypertension	Migraine Headache	Depression	Anxiety	Obesity
Number of patients with one comorbidity	4401	176	1327	33	2718	127	20
Number of patients with two comorbidities	4352	532	1474	43	1780	490	33
Number of patients with three or more comorbidities	2397	464	666	36	727	319	185

Fig. 2. Comorbidities details.

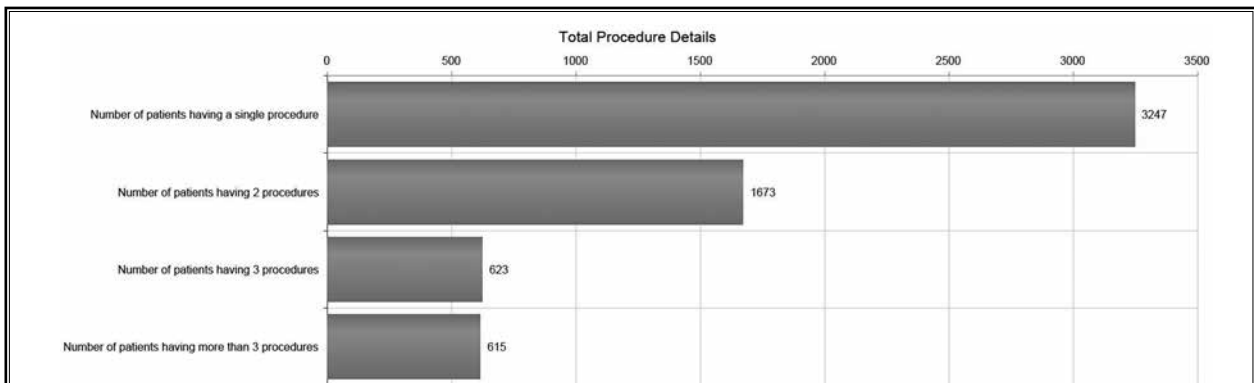


Fig. 3. Total procedure distribution.

dures performed at C5-6 (n = 6445, 53%) or C6-7 (n = 3899, 32%) (Fig. 4).

**Needle Information**

A 22-gauge, 3.5" Tuohy epidural needle was used in 11,346 procedures (93.2% of the overall cohort). A 20-gauge, 3.5" was used in 611 procedures (5%). The use of a 4.25" or longer needle was necessary in only a small number of procedures (n = 156; 1.3%).

**Complications**

We identified 136 complications out of 12,168 separate procedures (1.1% of the overall procedures). Upon review, we considered 7 of these complications to be serious (0.06% of the overall procedures) and the others to be minor (n = 129; 1% of the overall procedures) (Fig. 5). There were no deaths and no paralysis or permanent disability following any of the procedures.

The most common minor complication we observed was markedly increased pain immediately after the procedure. Several of these patients had suspected dural punctures with severe headache noted in the PACU. Several procedures were terminated prior to completion for patient anxiety, and we considered this to be a minor complication. Of note, none of the patients who had procedures terminated for anxiety received IV conscious sedation.

With regards to the serious complications, 3 patients experienced increased blood pressure during and after the procedure which did not respond adequately to management in the recovery room. These patients were transported to the hospital; 2 were discharged uneventfully from the emergency room

(ER) and one was admitted for persistent hypertension thought to be secondary to an underlying comorbidity. One patient experienced substernal chest pain in PACU and was transferred to the hospital, where hospital admission ruled out myocardial infarction. One patient with a suspected dural puncture and intrathecal air headache became hypertensive, nauseated, and diaphoretic as he was being discharged from PACU. He was transported to the ER where he improved under observation and was discharged from the ER uneventfully after a period of hours. In this subset of 5 serious complications, one patient was injected at C5-6, one at C6-7, and 2 at C7-T1.

The final 2 serious complications, which we considered to be the most serious, involved suspected spinal cord penetration with the Tuohy needle. The first case of cord penetration involved a 60-year-old man with a history of anterior cervical fusion at C5-6, severe right C4-5 foraminal stenosis, and right-sided carpal tunnel surgery in the distant past. He underwent cervical epidural injection at C7-T1 to treat chronic neck and right arm pain. On initial needle advancement, he experienced a severe paresthesia involving the right arm. The needle was repositioned with completion of the procedure. In PACU, the patient complained of persistent right arm pain, which continued after discharge. On post-procedure evaluation, he had slight right arm weakness without long tract (leg) signs or symptoms and no hyperreflexia.

Cervical magnetic resonance imaging (MRI) 6 weeks after the procedure showed mild myelomalacia of the dorsal spinal cord with worsened right C4-5 foraminal stenosis; both findings were new compared to MRI 6 months preceding the injection. Subsequent right arm electromyography (EMG) showed sequelae of carpal tunnel surgery but no cervical radiculopathy. The patient was lost to follow up 6 months after the

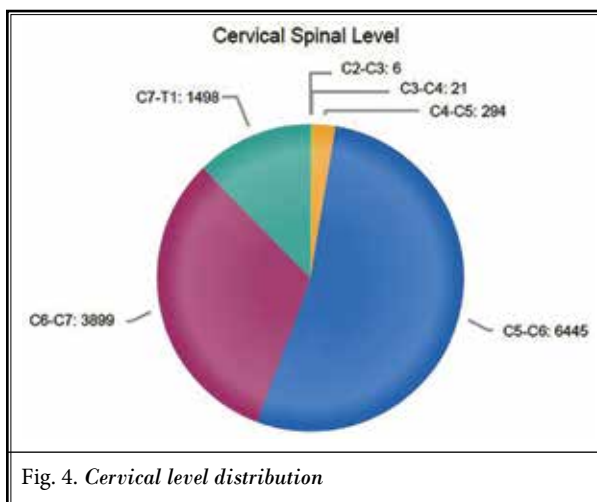


Fig. 4. Cervical level distribution

Level	Minor	Serious	No Complication
C2-3			6
C3-4	1		20
C4-5	6	1	287
C5-6	58	2	6379
C6-7	45	1	3851
C7-T1	19	3	1476

Fig. 5. Complication distribution

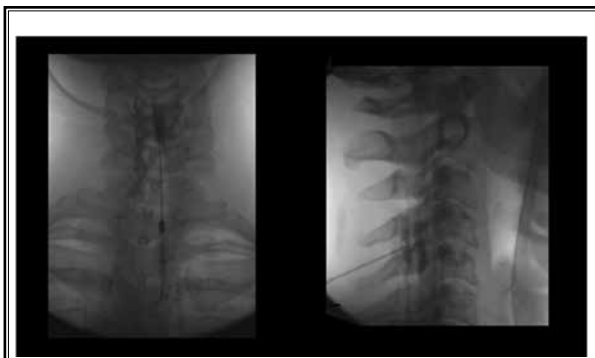


Fig. 6A. AP and lateral fluoroscopic images of C4-5 complication with cervical spine intraparenchymal needle injury:

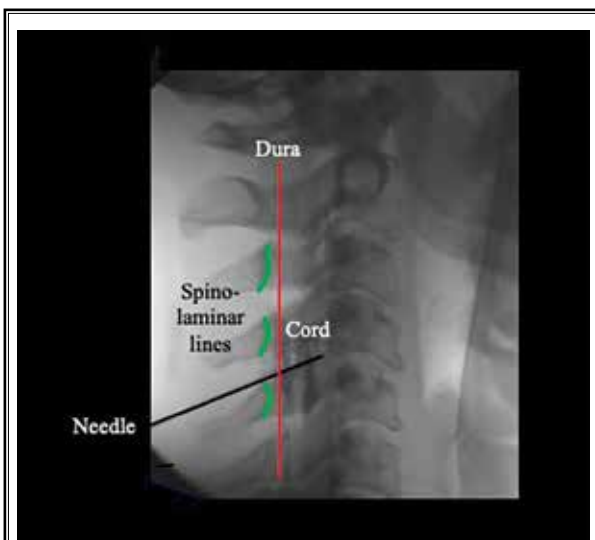

Fig. 6B. Same lateral image as Fig. 6 with markings and notation:

procedure, and we were unable to contact him to determine long-term outcome.

The second case of suspected cord penetration involved a 38-year-old woman who underwent cervical epidural at C4-5 for cervicalgia and cervicogenic headache without radicular pain. Cervical MRI 3 weeks prior to injection revealed moderate, multilevel cervical disc degeneration without neural impingement. During injection, the patient experienced severe right arm paresthesia. The physician repositioned the needle and continued the procedure, injecting x-ray contrast and steroid. Right arm pain and numbness persisted in PACU and beyond discharge. The saved fluoroscopy images

from the procedure reveal the tip of the Tuohy needle to be within the parenchyma of the spinal cord (Figs. 6A,B). It is unclear whether medication was injected into the cord. Post-procedure evaluation revealed right arm weakness without leg signs or symptoms. Cervical MRI 5 days after the injection revealed a cord lesion between C3 and C6 with hemorrhage and edema within the cord consistent with intraparenchymal inflammation. Repeat MRI 6 weeks after the procedure revealed reduced cord edema with formation of a cystic intra-parenchymal lesion at C4-5 consistent with cystic myelomalacia. We were able to contact this patient in 2020 (8 years after the injection) to determine long-term outcome. She stated during her injection, she experienced immediate pain in her right arm and numbness in her fingertips and that these symptoms improved over a period of months following the injection but never completely resolved. She told us she continues to experience right arm pain and numbness along with trouble with motor skills like brushing her teeth and washing her hair.

## DISCUSSION

Although epidural access at the C7-T1 level is advocated by some due to the hypothetically reduced risk of dural puncture and intrathecal injection given the wider epidural space at C7-T1 compared to more cephalad cervical levels, there was no increased risk of complications or dural penetration at any specific cervical level in our analysis of over 12,000 interlaminar cervical epidural steroid injections. Injections in our study were performed by skilled physicians using meticulous LOR technique with high-quality anteroposterior (AP), lateral, and oblique fluoroscopy, and an accurate assessment of the contrast dye pattern. Similar injections performed by less experienced, less skilled, or less qualified physicians using alternative techniques may have higher rates of complication.

In general, the purpose of most epidural steroid injections is to deposit steroid, usually mixed with local anesthetic, into the epidural space for therapeutic benefit. The epidural space can be entered at various levels and by various techniques (interlaminar, transforaminal, or via catheter), but the end goal is essentially the same – deposition of steroid into the epidural space at the site of inflammation and pathology. With disc-related nerve root irritation, the site of maximum pathology may be within the neural foramen at the junction between the posterolateral disc and the adjacent spinal nerve root or more diffusely throughout the epidural space. Although transforaminal epidural injections may target the ante-

rior epidural space and/or a specific dorsal root ganglion more selectively, these structures can be effectively targeted using interlaminar medication into the anterior epidural space and onto one or more targeted spinal nerve roots (see Appendix 2 and Images 1,2).

A disadvantage of interlaminar epidural injections performed at C7-T1 is that medication often moves caudally from the injection point and may not reach inflamed regions of the epidural space above C7-T1. Note that in Figs. 8 and 9, the bilateral C7 and C8 nerves are bathed in contrast, but there is no contrast visible at higher spinal levels. The intended target for epidural steroid is typically intraspinal inflammation at the spinal level of disc pathology. When there is inflammation at a cervical spinal level above C7-T1, intraspinal and epidural pressure at that level may be higher than pressure at adjacent levels, and it follows that when the epidural access needle tip is placed into the dorsal epidural space below the inflamed spinal level, injected medication including x-ray contrast, steroid, and local anesthetic may move caudally down the path of least resistance with medication failing to reach its intended more cephalad target (21). Although there is no data to determine how often contrast and medication move caudally and not cephalad when injected at C7-T1, experienced pain physicians know this to be a relatively common occurrence.

Disadvantages of C7-T1 injection go beyond failure to deliver medication to the intended target. Lateral fluoroscopic imaging at this level may not adequately visualize the coronal plane of the needle tip in relation to the lamina and ligamentum flavum because shoulders obstruct the view. Inadequate visualization of needle tip depth may contribute to dural puncture and penetration of the spinal cord at this level (22). Lateral imaging may also be difficult at C6-7, depending on body habitus. At C5-6, especially if the patient's shoulders are actively pulled toward the feet, it is usually possible to see the needle tip clearly in the coronal plane with true lateral fluoroscopy, which allows precise determination of needle tip depth in relation to the lamina. This visualization can be enhanced by placing the needle stylet back into the needle, which increases needle density. For lower cervical epidural injections, especially at C6-7 or C7-T1, the 50-degree contralateral oblique view may also help to visualize needle tip location by imaging oblique to the shoulders (Appendix 2, Images 3A-D).

Epidural hematoma is possible with any posterior interlaminar epidural injection, even when performed

with flawless technique in patients with no risk factors for spinal bleeding (25). However, in our study population, no patient experienced epidural hematoma, and there was no evidence that bleeding was more likely at any spinal level.

With regards to LOR technique, air is more compressible than water and allows for maximal transmission of 'tissue feel' from the needle tip to the injectionists' hand. Many experienced interventional pain physicians have changed from the classic saline-filled glass syringe with air-fluid interface common with blind epidural injections in anesthesiology practice to a plastic LOR syringe filled only with air. Filling the syringe with liquid or creating an air-water interface in the syringe does nothing to improve safety and attenuates the tactile information transmitted from tissues, through the needle shaft, and into the syringe-compressing fingers of the physician.

Lateral viewing of the cervical spine at the cervicocranial junction after contrast injection will allow detection of contrast dye coursing anteriorly and cephalad into the cerebral ventricles (Suppl Figs. 11,12). This fluoroscopic observation indicates dural penetration with intrathecal injection and requires repositioning of the needle tip, moving to a different spinal level, or abandoning the procedure altogether.

Although dural puncture with injection of intrathecal contrast is not desirable, it is a relatively minor, self-limited complication. A dural puncture may allow air bubbles to enter the intrathecal space and spinal fluid, causing an air bubble (pneumoencephalogram) headache. This type of immediate onset, non-positional headache noted when the patient sits up after a spinal injection typically indicates that air has entered the intrathecal space and floated cephalad into the cerebral ventricles and cranial vault (19,20). These "air bubble headaches" are typically self-limited and resolve over a period of hours without sequelae. Accidental injection of contrast into the intrathecal space is not life-threatening and, although some physicians believe accidental injection of particulate steroid into the intrathecal space may precipitate arachnoiditis, there is a lack of scientific evidence to substantiate this claim.

Perhaps the most serious untoward effect of dural penetration and intrathecal injection of local anesthetic-steroid mixtures is a "total spinal" block which could be life-threatening if adequate airway and blood pressure support are not provided. For this reason, cervical epidural injections should only be performed by qualified physicians skilled in and capable of man-

aging airway and blood pressure in a facility equipped for major resuscitation. Local anesthetic included in the spinal injectate offers the advantage of immediate short-term pain relief for an uncomfortable patient and may have diagnostic and/or therapeutic effects independent of the steroid but poses additional risk of local anesthetic spinal blockade if injected intrathecally. Lidocaine for epidural block may pose increased risk over bupivacaine because of the powerful, dose-dependent motor blockade with lidocaine compared to bupivacaine which preferentially blocks sensory fibers and has less effect on motor function. At higher doses, either local anesthetic can cause spinal anesthesia with airway compromise, but at lower doses, bupivacaine may be a safer anesthetic for epidural injection because of its motor sparing effect. The duration of action for bupivacaine is significantly longer, which is an advantage for post-procedure pain relief, but poses minimal increased risk with immediate spinal block since both lidocaine and bupivacaine have duration of action long enough to require prolonged airway support. Although the duration of action of lidocaine is shorter than bupivacaine, it is certainly long enough to cause fatal respiratory compromise, so the short duration of action of the local anesthetic is not advantageous were accidental intrathecal injection to occur.

### Limitations

Although our data encompasses 14 years of private practice pain clinic experience with cervical epidural

injection, the data set is incomplete, and we did not assess long-term efficacy of this procedure. Data was mined from procedure templates and PACU templates which were occasionally not filled out completely, and data were not completely recorded for every procedure. To capture all serious complications, we cross-checked complication data recorded in the procedure, and PACU templates with nursing notes from PACU discharge and with records of prolonged PACU stays transports from PACU to a hospital facility and malpractice claims. Nonetheless, we may have missed delayed complications. Most importantly, our study is focused on safety and short-term complications. We did not mine data for longer-term outcomes and can draw no conclusions on efficacy of these injections other than the positive subjective opinions of the doctors who provided them and the fact that many patients returned for repeat injections for therapeutic benefit.

### CONCLUSION

Our article supports the contention that interlaminar cervical epidural injections above C7-T1 can be safe. Retrospective analysis shows that posterior cervical epidural steroid injections performed by experienced pain physicians using fluoroscopic guidance in our ambulatory surgery center at spinal levels ranging from C2-3 down to C7-T1 resulted in a minor complication rate of approximately 1% with very rare serious complications (0.06%). Complication rates were not increased at spinal levels cephalad to C7-T1.

Supplemental material available at [www.painphysicianjournal.com](http://www.painphysicianjournal.com)

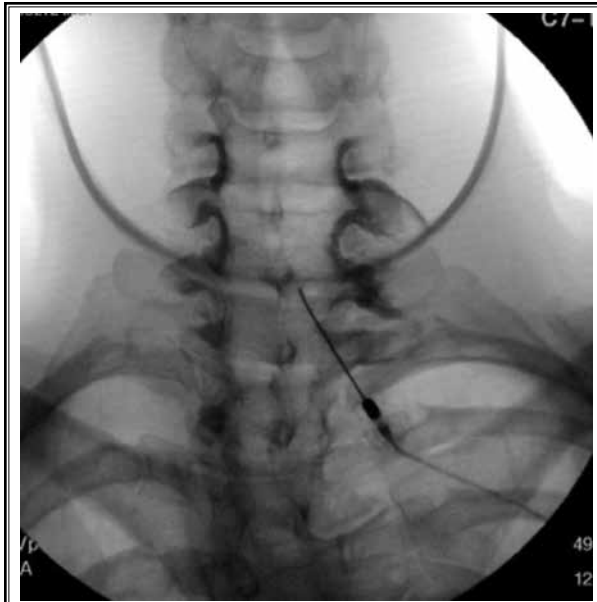### REFERENCES

1. Robecchi P, Capra AL. L'idrocortisone (composto F), prime esperienze cliniche in campo reumatologico. (In Italian). *Minerva Med* 1952; 2:1259-1263.
2. Cousins MJ. Epidural neural blockade. In: Cousins MJ, Bridenbaugh PO (eds). *Neural Blockade in Clinical Anesthesia and Management of Pain*. Lippincott, Philadelphia, PA, 1980, p 262.
3. Bromage PR (ed). *Epidural Analgesia*. WB Saunders, Philadelphia, PA, 1978.
4. Rowlingson JC, Kirschenbaum LP. Epidural analgesic techniques in the management of cervical pain. *Anesth Analg* 1986; 65:938-942.
5. Mangar D, Thomas PS. Epidural steroid injections in the treatment of cervical and lumbar pain syndromes. *Reg Anesth* 1991; 16:246.
6. Ferrante FM, Wilson SP, Iacobo C, Orav EJ, Rocco AG, Lipson S. Clinical classification as a predictor of therapeutic outcome after cervical epidural steroid injection. *Spine (Phila Pa 1976)* 1993; 18:730-736.
7. Stav A, Ovidia L, Sternberg A, Kaadan M, Weksler N. Cervical epidural steroid injection for cervicobrachialgia. *Acta Anaesthesiol Scand* 1993; 37:562-566.
8. Castagnera L, Maurette P, Pointillart V, Vital JM, Erny P, Sénégas J. Long-term results of cervical epidural steroid injection with and without morphine in chronic cervical radicular pain. *Pain* 1994; 58:239-243.
9. Grenier B, Castagnera L, Maurette P, Erny P, Senegas J. Nevralgie cervico-brachiale chronique traitée par injection peridurale cervicale de corticoids. Resultants a long terme. *Ann Fr Anesth Reanim* 1995; 14:484-488.
10. Manchikanti L, Malla Y, Cash KA, Pampati V, Hirsch JA. Comparison of effectiveness for fluoroscopic cervical interlaminar epidural injections with or without steroid in cervical post-surgery syndrome. *Korean J Pain* 2018; 31:277-288.
11. Manchikanti L, Pampati V, Parr Iii A, et al. Cervical interlaminar epidural injections in the treatment of cervical

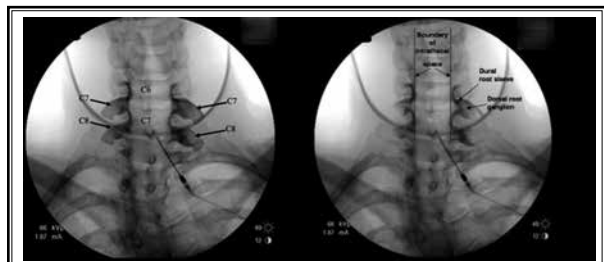


- disc herniation, post surgery syndrome, or discogenic pain: Cost utility analysis from randomized trials. *Pain Physician* 2019; 22:421-431.
12. Manchikanti L, Cash KA, Pampati V, Malla Y. Two-year follow-up results of fluoroscopic cervical epidural injections in chronic axial or discogenic neck pain: A randomized, double-blind, controlled trial. *Int J Med Sci* 2014; 11:309-320.
  13. Manchikanti L, Cash KA, Pampati V, Wargo BW, Malla Y. A randomized, double-blind, active control trial of fluoroscopic cervical interlaminar epidural injections in chronic pain of cervical disc herniation: results of a 2-year follow-up. *Pain Physician* 2013; 16:465-478.
  14. Kaye AD, Manchikanti L, Abdi S, et al. Efficacy of epidural injections in managing chronic spinal pain: a best evidence synthesis. *Pain Physician* 2015; 18:E939-E1004.
  15. Manchikanti L, Nampiaparampil DE, Candido KD, et al. Do cervical epidural injections provide long-term relief in neck and upper extremity pain? A systematic review. *Pain Physician* 2015; 18:39-60.
  16. Manchikanti L, Knezevic NN, Navani A, et al. Epidural interventions in the management of chronic spinal pain: American Society of Interventional Pain Physicians (ASIPP) comprehensive evidence-based guidelines. *Pain Physician* 2021; 24:S27-S208.
  17. Manchikanti L, Sanapati MR, Pampati V, Boswell MV, Kaye AD, Hirsch JA. Update on reversal and decline of growth of utilization of interventional techniques in managing chronic pain in the Medicare population from 2000 to 2018. *Pain Physician* 2019; 22:521-536.
  18. Manchikanti L, Sanapati MR, Soin A, et al. An updated analysis of utilization of epidural procedures in managing chronic pain in the Medicare population from 2000 to 2018. *Pain Physician* 2020; 23:111-126.
  19. Manchikanti L, Pampati V, Soin A, Sanapati MR, Kaye AD, Hirsch JA. Declining utilization and inflation-adjusted expenditures for epidural procedures in chronic spinal pain in the Medicare population. *Pain Physician* 2021; 24:1-15.
  20. Huston CW. Cervical epidural steroid injections in the management of cervical radiculitis: interlaminar versus transforaminal. A review. *Curr Rev Musculoskelet Med* 2009; 2:30-42.
  21. Hodges SD, Castleberg RL, Miller T, Ward R, Thornburg C. Cervical epidural steroid injection with intrinsic spinal cord damage. Two case reports. *Spine (Phila Pa 1976)* 1998; 23:2137-2142.
  22. Derby R, Lee SH, Kim BJ, Chen Y, Seo KS. Complications following cervical epidural steroid injections by expert interventionalists in 2003. *Pain Physician* 2004; 7:445-449.
  23. Rathmell JP, Benzon HT, Dreyfuss P, et al. Safeguards to prevent neurologic complications after epidural steroid injections: consensus opinions from a multidisciplinary working group and national organizations. *Anesthesiology* 2015; 122:974-984.
  24. Benzon HT, Huntoon MA, Rathmell JP. Improving the safety of epidural steroid injections. *JAMA* 2015; 313:1713-1714.
  25. Manchikanti L, Falco FJE, Benyamin RM, Gharibo CG, Candido KD, Hirsch JA. Epidural steroid injections safety recommendations by the Multi-Society Pain Workgroup (MPW): more regulations without evidence or clarification. *Pain Physician* 2014; 17:E575-E588.
  26. Racoosin JA, Seymour SM, Cascio L, Gill R. Serious neurologic events after epidural glucocorticoid injection--the FDA's risk assessment. *N Engl J Med* 2015; 373:2299-2301.
  27. Manchikanti L, Candido KD, Singh V, et al. Epidural steroid warning controversy still dogging FDA. *Pain Physician* 2014; 17:E451-E474.
  28. Manchikanti L, Malla Y, Cash KA, Pampati V. Do the gaps in the ligamentum flavum in the cervical spine translate into dural punctures? An analysis of 4,396 fluoroscopic interlaminar epidural injections. *Pain Physician* 2015; 18:259-266.
  29. Baker R, Dreyfuss P, Mercer S, Bogduk N. Cervical transforaminal injection of corticosteroids into a radicular artery: a possible mechanism for spinal cord injury. *Pain* 2002; 103:211-215.
  30. Manchikanti L, Malla Y, Wargo BW, Cash KA, Pampati V, Fellows B. A prospective evaluation of complications of 10,000 fluoroscopically directed epidural injections. *Pain Physician* 2012; 15:131-140.
  31. White YS, Bell DS, Mellick R. Sequelae to pneumoencephalography. *J Neurol Neurosurg Psychiatry* 1973; 36:146-151.
  32. Leeds NE, Kieffer SA. Evolution of diagnostic neuroradiology from 1904-1999. *Radiology* 2000; 217:309-318.
  33. Usubiaga JE, Wikinski JA, Usubiaga LE. Epidural pressure and its relation to spread of anesthetic solutions in the epidural space. *Anesth Analg* 1967; 46:440-446.
  34. Landers M. Spinal cord injury during attempted cervical interlaminar epidural injection of steroids. *Pain Med* 2018; 19:652-657.
  35. Manchikanti L, Gruber TJ, Prabhakar H, Hirsch JA. Acute epidural hematoma following a cervical epidural injection in a patient without bleeding risk. *IPM Reports* 2018; 2:119-126.
  36. Manchikanti L, Schultz DM, Falco FJE. Cervical epidural injections. In: Manchikanti L, Kaye AD, Falco FJE, Hirsch JA (eds). *Essentials of Interventional Techniques in Managing Chronic Spinal Pain*. Springer, New York, NY, 2018, pp 209-240.

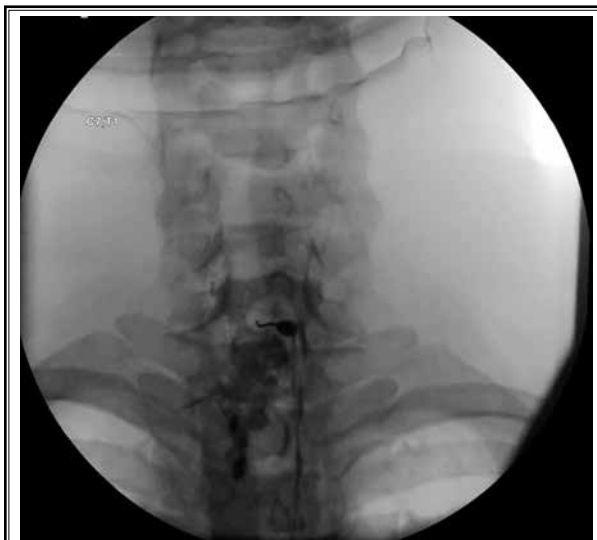



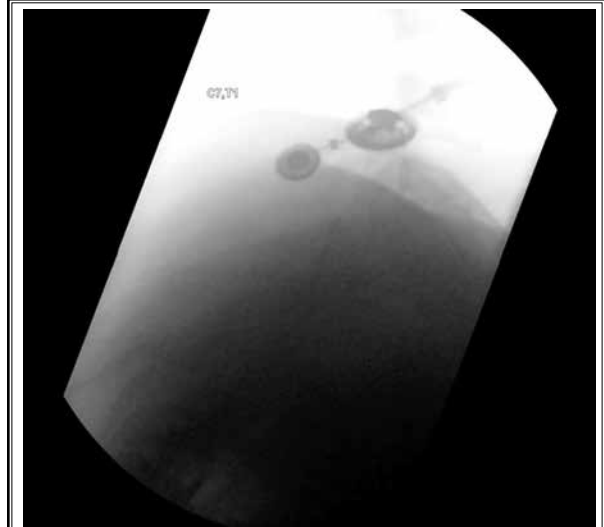Appendix Image 1. C7-T1 posterior interlaminar epidural injection with contrast covering bilateral C7 and C8 nerve roots. Note that contrast does not ascend higher than C6.



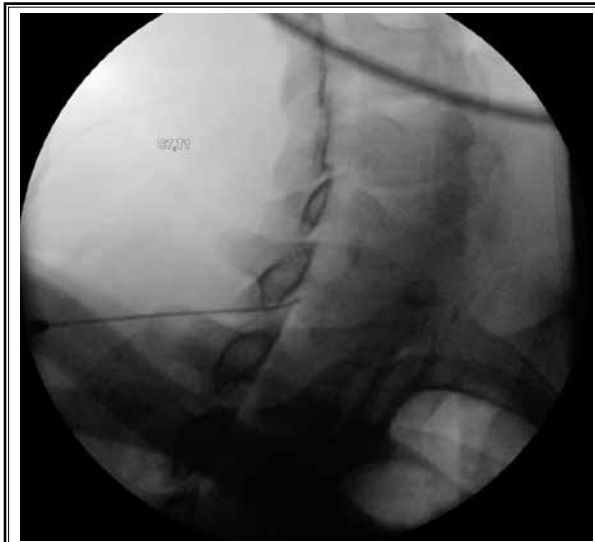Appendix Image 2. Same image as Fig. 7 with markings and notations:



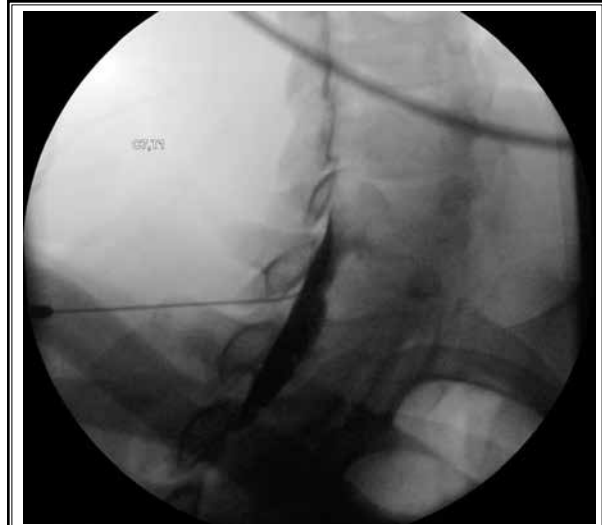
Appendix Image 3A. AP view of C7-T1 epidural steroid injection in obese patient:



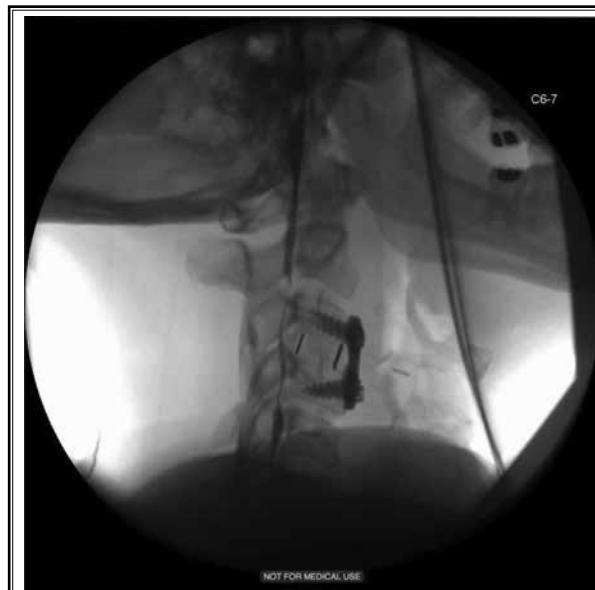Appendix Image 3B. Lateral view of same injection with shoulders blocking visual of needle tip:



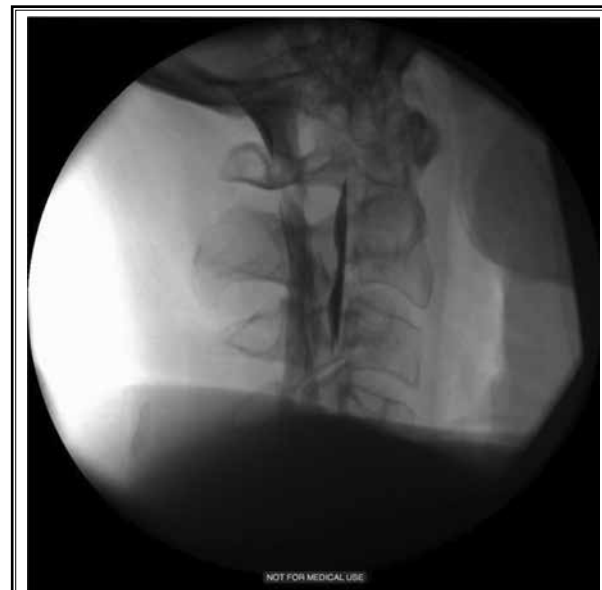Appendix Image 3C. 50-degree oblique view of same injection with needle tip clearly visible beneath the lamina. Note the small amount of air moving caudally within the dorsal epidural space:



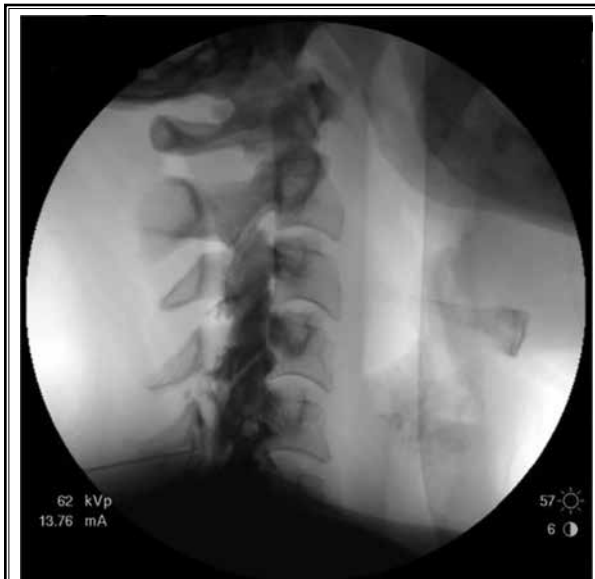Appendix Image 3D. 50-degree oblique view of same injection after x-ray contrast injection:



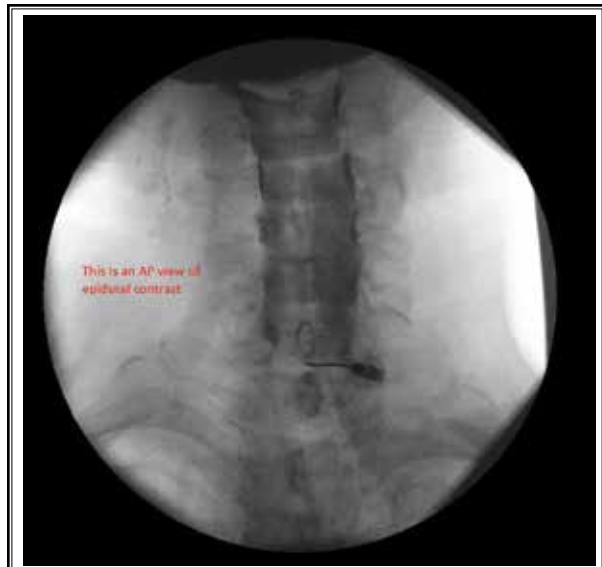Appendix Image 4. Typical cervical epidurogram, AP and lateral view C4-5.



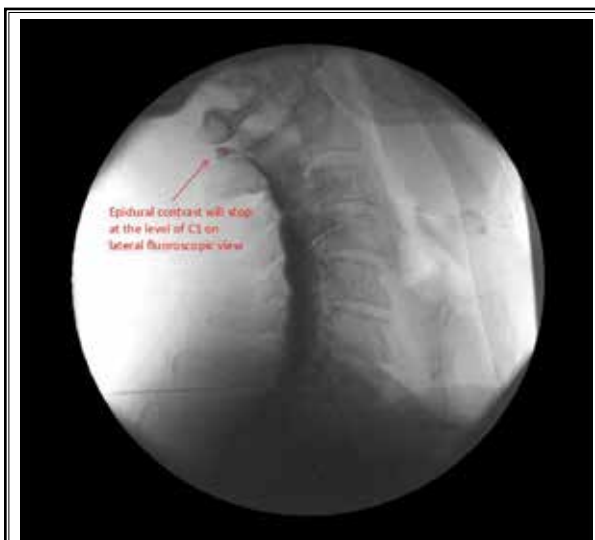Appendix Image 5. Intrathecal contrast. Contrast moving into the ventricles is easily seen on lateral view but difficult to identify on AP view. Note that the AP view in Fig. 10D is similar to the AP view in Fig. 11.



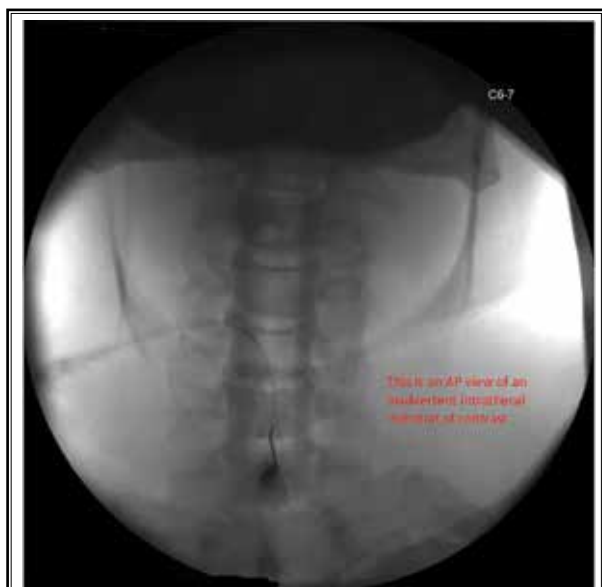Appendix Image 6. Typical epidurogram on lateral view with C5-6 injection using a low volume of contrast. The needle tip is just ventral to the spinolaminar line, and air is filling the posterior epidural space up to the top of the epidural space at C1-2.



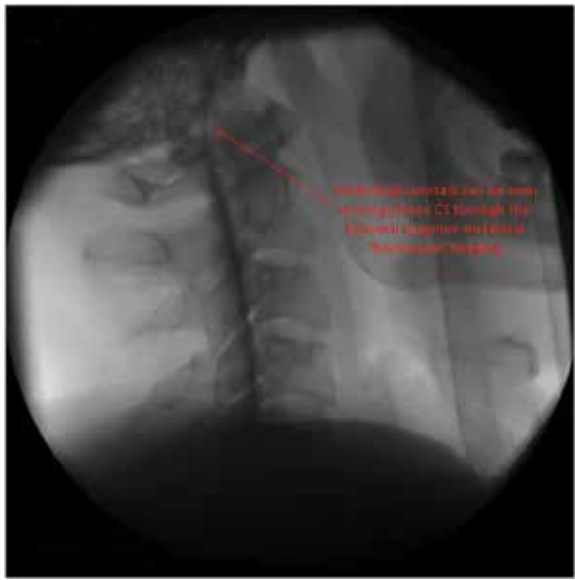Appendix Image 7. An AP view of epidural contrast injected at C7-T1. The right C7 dorsal root ganglion is faintly outlined by contrast, indicating epidural injection.



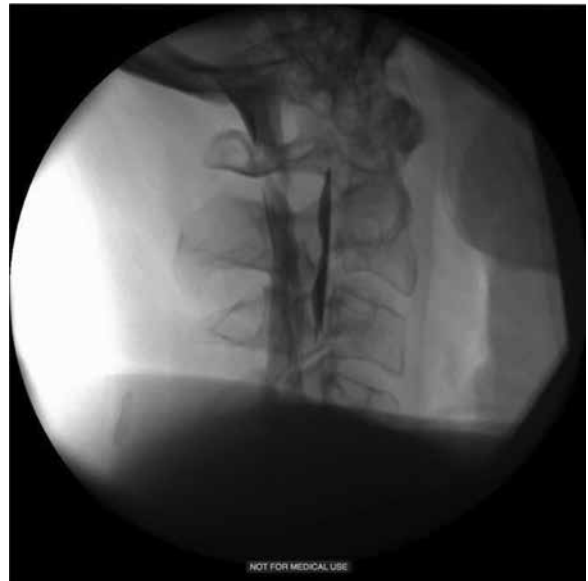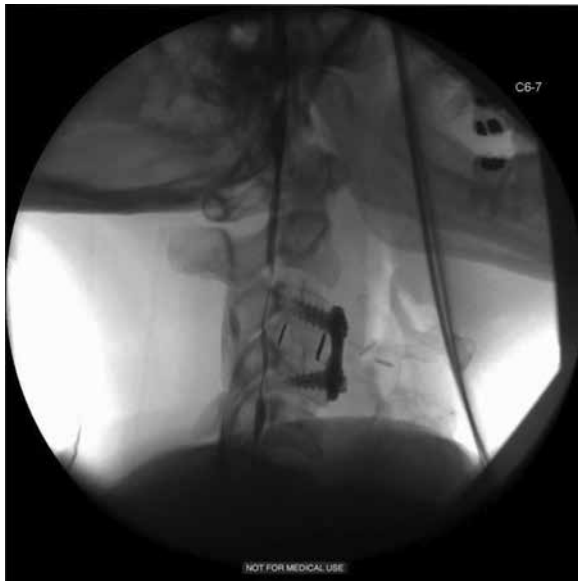Appendix Image 8. A lateral view of the same injection shown in Fig. 7. Note the needle tip is difficult to see clearly at C7-T1, even with shoulders pulled downward. The epidural contrast shows the typical epidural pattern stopping posteriorly at C1-2.



Appendix Image 9. An AP view of intrathecal contrast. Note that Image 7 and Image 9 look very similar, illustrating that it is difficult to determine whether contrast is epidural or intrathecal from an AP image.



Appendix Image 10. *The lateral view of contrast from the same procedure as Image 9. It is now obvious that contrast is moving ventrally into the cranium, indicating intrathecal injection.*



Appendix Image 11 (left) and 12 (right). *Safety of Interlaminar Cervical Epidural Injections: Experience With 12,168 Procedures in a Single Pain Clinic.*